

McLAREN IMAGING CENTER  
501 S. Ballenger Hwy., Suite B • Flint, MI 48532  
810-342-4800

**DEPARTMENT OF RADIOLOGY  
CEREBROVASCULAR EVALUATION**

Pt. Name: \_\_\_\_\_ Date: \_\_\_\_ / \_\_\_\_ / \_\_\_\_

Sonographer: Pt. #: \_\_\_\_\_ Attending Dr.: \_\_\_\_\_ Age: \_\_\_\_\_ Sex: M / F

Diagnosis: \_\_\_\_\_ No. of Films: \_\_\_\_\_

**HISTORY**

Previous CVA's or TIA's  Yes  No

Weakness and / or Numbness  Yes  No

Dysphasia  Yes  No

Dizziness / Light Headedness / Black-out Spells  Yes  No

Visual Disturbance or Blindness  Yes  No

Headaches  Yes  No

Impaired Memory / confusion  Yes  No

Hypertension  Yes  No

Cardiac Disorder  Yes  No

Diabetes  Yes  No

Smoking  Yes  No

Bruits  Yes  No

Other: \_\_\_\_\_

Medication: \_\_\_\_\_

Previous Doppler Exam (Where): \_\_\_\_\_

Anogios: \_\_\_\_\_

Surgery: \_\_\_\_\_

– See Reverse –



**DEPARTMENT OF RADIOLOGY**  
**CEREBROVASCULAR EVALUATION**

Pt. Name: \_\_\_\_\_ Date: \_\_\_\_ / \_\_\_\_ / \_\_\_\_

**PLAQUE** Right Left

**Location and Plane (A,P,M,L.)**

CCA: \_\_\_\_\_

Bulb: \_\_\_\_\_

ICA: \_\_\_\_\_

ECA: \_\_\_\_\_

**Characteristics C B I E C B I E**

Surface – Smooth / Irreg

Texture – Homo / Hetero

% Diameter Stenosis

Plaque Thickness

Calcification

C	B	I	E	C	B	I	E

**DEGREE OF STENOSIS**

**P.S.V.**

CCA: \_\_\_\_\_

ICA: \_\_\_\_\_

ECA: \_\_\_\_\_

IC / CC Ratio: \_\_\_\_\_

**P.D.V.**

CCA: \_\_\_\_\_

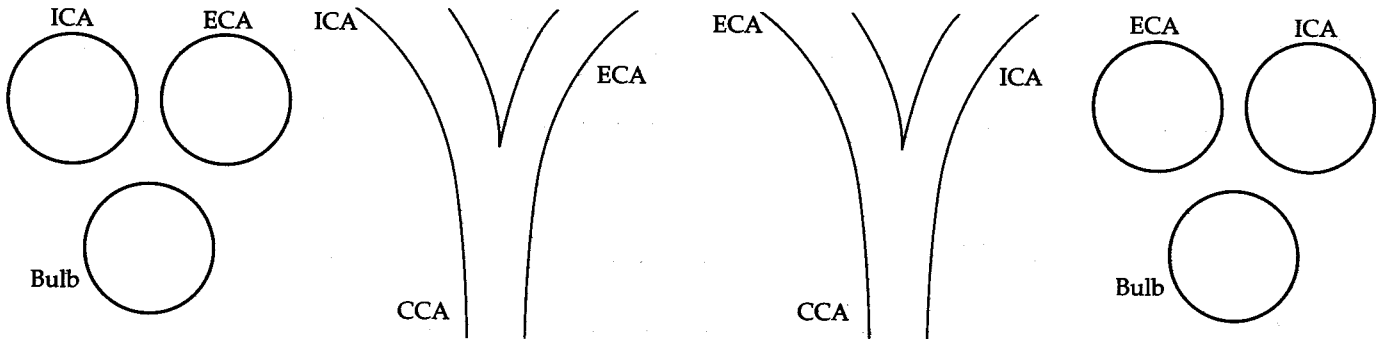
ICA: \_\_\_\_\_

IC / CC Ratio: \_\_\_\_\_

**Spectral Broadening**

ICA: \_\_\_\_\_

Vertebral Flow: \_\_\_\_\_



Comments: \_\_\_\_\_

PT.

MR.#/P.M.

DR.